

REVIEW ARTICLE

Julie R. Ingelfinger, M.D., *Editor*

Kidney Diseases Associated with Human Immunodeficiency Virus Infection

Scott D. Cohen, M.D., M.P.H., Jeffrey B. Kopp, M.D., and Paul L. Kimmel, M.D.

HIGHLY ACTIVE ANTIRETROVIRAL THERAPY HAS LED TO DRAMATIC IMPROVEMENT in the life expectancy of persons with human immunodeficiency virus (HIV) infection.¹⁻³ Approximately 36.7 million people live with HIV infection worldwide,^{1,2,4,5} and there were approximately 2.1 million cases of incident HIV infection globally in 2015.⁵ Almost three quarters of HIV-infected persons live in sub-Saharan Africa.^{1,2,4,6} Although 18.2 million people worldwide were receiving antiretroviral therapy by 2016,⁵ only 40% of HIV-infected persons in sub-Saharan Africa received antiretroviral therapy as of 2014.⁷ The prevalence of HIV infection is much lower in the United States than in sub-Saharan Africa. Approximately 1.2 million persons in the United States have HIV infection, and the annual incidence has been stable at approximately 50,000 infections over the past decade.^{5,8}

Kidney disease, which is a common complication of HIV infection and its treatment, may shorten the lifespan of patients.^{4,9,10} Soon after the index cases of the acquired immunodeficiency syndrome (AIDS) were identified in 1980, various kidney diseases associated with AIDS were recognized.¹⁰ The spectrum of HIV-associated renal diseases includes diseases that are directly associated with infection, those that are linked to the systemic immune response to infection, those that develop as a consequence of superinfections, and those that are associated with the treatment of HIV infection (Table 1).¹⁰ Since the introduction of molecular tools to detect HIV within tissues, our understanding of the pathogenesis of common kidney diseases, such as focal segmental glomerulosclerosis and immune-complex renal disease, in persons with HIV infection has improved. Over the past two decades, antiretroviral therapy has converted HIV infection to a chronic illness, with associated changes in the incidence, type, and severity of HIV-associated kidney diseases. Current antiretroviral therapy regimens suppress viral replication, but this treatment may result in chronic inflammation, premature aging, and metabolic disorders (e.g., diabetes, hyperlipidemia, and abnormal body fat composition) — conditions that are associated with chronic kidney disease.¹¹⁻¹⁵

From the Division of Renal Diseases and Hypertension, Department of Medicine, George Washington University, Washington, DC (S.D.C., P.L.K.); and the National Institute of Diabetes and Digestive and Kidney Diseases, National Institutes of Health, Bethesda, MD (J.B.K., P.L.K.). Address reprint requests to Dr. Kimmel at National Institute of Diabetes and Digestive and Kidney Diseases, National Institutes of Health, Rm. 6707, Democracy Blvd., Bethesda, MD 20892, or at kimmelp@extra.niddk.nih.gov.

N Engl J Med 2017;377:2363-74.

DOI: 10.1056/NEJMra1508467

Copyright © 2017 Massachusetts Medical Society.

EVALUATION OF RENAL SYNDROMES IN HIV INFECTION

Patients with HIV infection are at increased risk for both acute kidney injury and chronic kidney disease.^{4,9,10,12,16-18} Untreated HIV infection, as well as antiretroviral therapy, are associated with kidney disease. Antiretroviral therapy is a double-edged sword: although it can lead to improvement in the life expectancy of persons with HIV infection, it can also increase clinical uncertainty regarding changes in renal function in this population. The approaches to evaluating acute kidney injury and chronic kidney disease are shown in Figure 1. Given the breadth of causes of these kidney diseases, a kidney biopsy may be necessary to establish a diagnosis.

Microalbuminuria, a key sign of kidney disease but also a manifestation of the metabolic syndrome and vascular dysfunction, is present in 10 to 15% of patients

Table 1. Kidney Diseases in Patients with Human Immunodeficiency Virus Infection.

Acute kidney injury
Prerenal azotemia
Acute tubular necrosis
Rhabdomyolysis
Antiretroviral therapy–associated acute kidney injury
Tubulointerstitial nephritis
Immune reconstitution syndrome
HIV-associated nephropathy
HIV immune-complex kidney disease
IgA nephropathy
Postinfectious glomerulonephritis
Mesangial proliferative glomerulonephritis
Lupus-like glomerulonephritis
Membranoproliferative glomerulonephritis
Cryoglobulinemic glomerulonephritis
Other glomerulonephritides
Thrombotic microangiopathies
Urinary tract obstruction
Bladder outlet obstruction
Ureteral obstruction
Intrinsic: fungus balls, blood clots
Extrinsic: retroperitoneal fibrosis, lymphadenopathy
Chronic kidney disease
HIV-associated nephropathy
HIV immune-complex kidney disease
Antiretroviral therapy–associated chronic kidney disease
Tubulointerstitial nephritis
Crystal nephropathy
Tenofovir disoproxil fumarate–induced nephrotoxicity
Tubulointerstitial renal disease
Diffuse infiltrative lymphocytosis syndrome
Opportunistic infections of the kidney parenchyma
Viral infections
Cytomegalovirus
Parvovirus
Herpes simplex
Other infections
Fungal infections
Mycobacterial infections, typical and atypical
Mycoplasma
Microsporidia
Bacterial pyelonephritis
Infiltrative lesions of the kidney
Lymphoma
Kaposi's sarcoma

with HIV infection.¹⁹ The prevalence of a reduced glomerular filtration rate is 2 to 10% but varies across populations.²⁰ Depletion of intravascular volume is probably the most common cause of acute kidney injury.^{16,17} Hospitalized patients with HIV infection who have sepsis or who are receiving nephrotoxic medications are at increased risk for acute tubular necrosis and acute interstitial nephritis. Acute kidney injury and chronic kidney disease may be closely intertwined over time; chronic kidney disease often precedes acute kidney injury but could also develop or worsen after acute kidney injury, frequently culminating in end-stage renal disease.^{18,21}

Equations for calculating the estimated glomerular filtration rate have been evaluated in patients with HIV infection^{22,23}; the estimated glomerular filtration rate can be calculated on the basis of serum creatinine concentration or, in patients with reduced muscle mass, serum cystatin C level and provides clinical guidance for drug dosing. Trimethoprim, cobicistat, and HIV integrase inhibitors inhibit proximal renal tubular secretion of creatinine, which may increase the serum creatinine concentration²⁴ without changing the glomerular filtration rate. The serum creatinine concentration does not typically increase more than 15 to 30% with such medications.²⁵ Greater increases in the serum creatinine concentration should prompt an evaluation for acute kidney injury.

Estimation of glomerular filtration rate that is based on the cystatin C level may help to identify the development of chronic kidney disease, particularly in patients with moderately diminished creatinine-based estimated glomerular filtration rate and muscle wasting, in whom the serum creatinine concentration may not accurately reflect the glomerular filtration rate.⁹ Because cystatin C levels may be elevated as a result of inflammation, the cystatin C–based estimated glomerular filtration rate must be used cautiously.

HIV-ASSOCIATED NEPHROPATHY

Before the availability of antiretroviral therapy, HIV-associated nephropathy, initially reported by research groups in Miami and New York in 1984,²⁶⁻²⁸ typically presented with nephrotic-range proteinuria and decreased renal function.^{4,9,10} Currently, presentation varies depending on whether antiretroviral therapy has been provided.

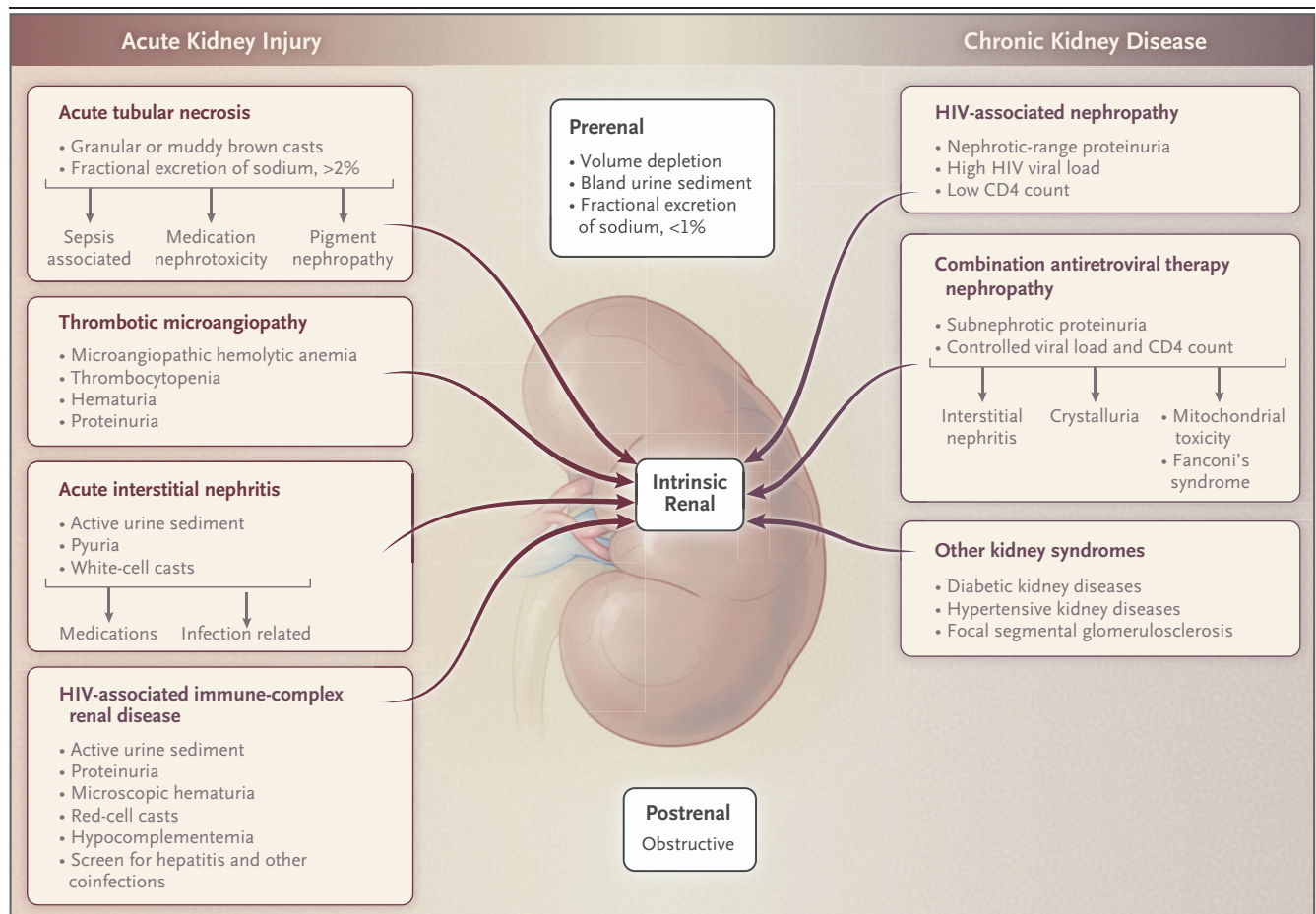


Figure 1. Approaches to Evaluating Kidney Disease in Patients with HIV Infection.

In the evaluation of acute kidney injury in patients with human immunodeficiency virus (HIV) infection, the differential diagnosis of a sudden reduction in the glomerular filtration rate is made with a close microscopic examination of a urine sample to help differentiate classic prerenal, intrinsic renal, and postrenal obstructive causes. Evaluation of urinary osmolality and sodium and creatinine concentration may add value. The evaluation of chronic kidney disease in HIV-infected patients requires a careful history and physical examination to assess traditional risk factors for renal disease, in addition to unique clinical characteristics of HIV-associated renal diseases. Evaluation of urinary protein excretion is helpful in establishing diagnostic categories. A renal biopsy is often necessary to confirm the diagnosis and inform prognosis and treatment. Acute tubular necrosis and acute interstitial nephritis are usually manifestations of acute kidney injury. HIV-associated nephropathy, HIV immune-complex kidney disease, kidney disease of thrombotic microangiopathy, and nephrotoxicity can be manifestations of either acute kidney injury or chronic kidney disease.

Edema is variably present, because some patients with HIV-associated renal disease may have malnutrition or salt wasting from renal tubular injury.²⁹

HIV-associated nephropathy affects all renal tissue compartments, including glomeruli, tubules, and interstitium (Figs. S1 and S2 in the Supplementary Appendix, available with the full text of this article at NEJM.org). A collapsing form of focal segmental glomerulosclerosis is a typical manifestation of HIV-associated nephropathy and is characterized by an increased number of cells in the podocyte compartment; these cells may be podocyte progenitors.³⁰ Focal segmental glomerulosclerosis shows segmental glomerular

scarring, with only some glomeruli affected. Other histologic features include microcystic renal tubular dilatation, interstitial inflammation, fibrosis, and tubuloreticular inclusion bodies, which are detected occasionally in glomerular endothelial cells by electron microscopy.^{4,9,10}

The prevalence of HIV-associated nephropathy has decreased dramatically since the introduction of antiretroviral therapy and consequent effective suppression of viral replication.^{4,31} Before the antiretroviral therapy era, the prevalence of HIV-associated nephropathy was 3.5 to 10.0% among HIV-infected persons in the United States.^{4,10,31} Over the past 20 years, the incidence

of end-stage renal disease attributed to HIV infection has declined and then plateaued, whereas the prevalence of end-stage renal disease in this patient population continues to increase, because patients live longer with effective antiretroviral therapy.³² The annual incidence of 800 to 900 cases of HIV-associated end-stage renal disease has been stable for several years.³²

The prevalence of HIV-associated nephropathy varies worldwide, with the highest rates reported in sub-Saharan Africa.⁶ In the United States, HIV-associated nephropathy occurs primarily in persons of African descent, particularly in those with markedly reduced CD4 counts and elevated viral loads.⁴ HIV-associated nephropathy probably arises because of complex interactions among host factors (especially genetics), pathogen characteristics (particularly renal viral protein expression), and environmental and behavioral factors (the most important of which may be access to care and antiretroviral therapy with effective viral suppression) (Fig. 2).

In the kidneys, HIV RNA has been shown to be localized to podocytes and tubular epithelial cells, which perhaps explains why these cells show striking abnormalities in HIV-associated nephropathy. The HIV regulatory protein Nef and the HIV accessory protein Vpr, when overexpressed in mice, reproduce the HIV-associated nephropathy syndrome, which suggests that these proteins play pathogenic roles in HIV-associated nephropathy.^{4,10}

The genetic predisposition to HIV-associated nephropathy among patients of African descent is due largely to variants in the *APOL1* gene, encoding apolipoprotein L1.^{33,34} *APOL1* is a minor protein constituent of particular high-density lipoprotein particles that comprise two forms of trypanosome lytic factor.³⁵ In vitro data show that *APOL1* variants help in killing *Trypanosoma brucei*, the cause of African sleeping sickness.^{33,36} Recent findings regarding the *APOL1* renal risk variants G1 and G2 (in contrast to the common allele G0) implicate both variants in the resistance to subspecies of *T. brucei*, which suggests that the variants evolved to kill *T. brucei* subspecies.³⁶ Both variants are limited to populations of sub-Saharan descent.⁴

APOL1 risk variants are also associated with non-HIV chronic kidney disease, including focal segmental glomerulosclerosis and hypertension-associated arterionephrosclerosis.^{33,37} Risk-allele

frequencies are approximately 50% among West Africans and approximately 35% among African Americans. Approximately 13% of African Americans are at increased genetic risk for chronic kidney disease.⁴

APOL1 renal risk variants are strongly associated with HIV-associated nephropathy.^{37,38} Interactions between gene and environment may modify the strength of the associations. South African patients with HIV-associated nephropathy who have a single *APOL1* risk allele have a higher risk of kidney disease than patients who have no *APOL1* risk alleles, which is consistent with a dominant gain-of-function effect of the *APOL1* risk allele, as seen in animal models,³⁸⁻⁴¹ rather than a recessive loss-of-function effect.

HIV infection stimulates interferon expression.⁴² Expression of *APOL1*, an innate immunity gene, is stimulated by interferon,⁴³ which probably explains in part why associations with *APOL1* renal risk variants are so strong in HIV infection. *APOL1* risk alleles are incompletely penetrant, as evidenced by the fact that kidney disease does not develop in most carriers of two risk alleles, which suggests that modulation by environmental or other genetic factors is also needed (Fig. 2). However, in some patients, increased expression of risk alleles and their products, which is stimulated by interferon, may be sufficient to induce glomerulopathy.²⁹ Recent evidence suggests that serum urokinase-type plasminogen activator receptor, an inflammation marker, may interact with *APOL1*, thereby activating the α V β 3 integrin receptor, which is expressed in podocytes, and perhaps promoting kidney disease in genetically susceptible persons.⁴⁴ In *APOL1* transgenic mice, reduction in *APOL1* gene expression is associated with improved renal histologic findings and less azotemia and albuminuria.⁴¹ Because the nephropathies that are most strongly associated with *APOL1* variants are podocytopathies,⁴⁵ it is likely that the expression and products of *APOL1* variants damage podocytes and possibly other renal cells. Emerging evidence suggests a direct role of the products of *APOL1* variants in nephropathogenesis,^{40,41} including alterations in membrane ion flux⁴⁶; altered mitochondrial,⁴⁷ endolysosomal, and autophagic function^{39,41}; and increased cellular inflammatory pathways, including activation of protein kinase R.^{29,41} *APOL1* variants have not been associated with an in-

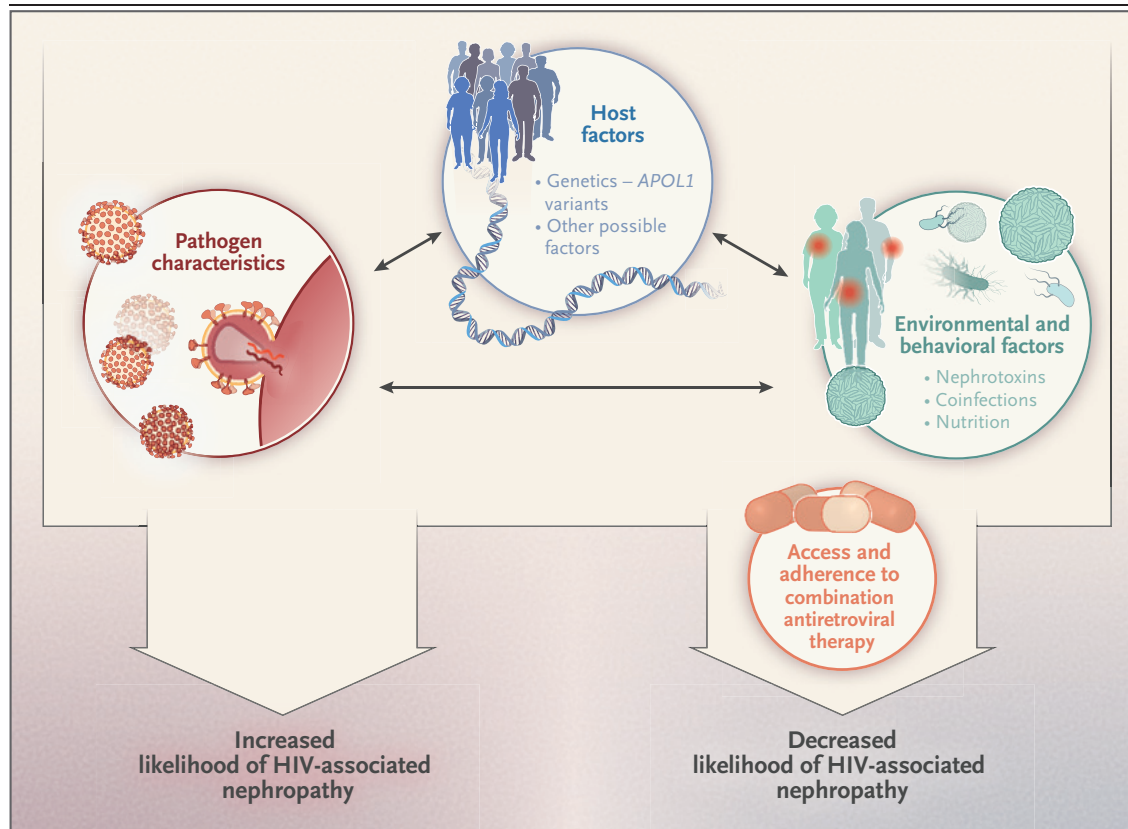


Figure 2. Pathogenesis of HIV-Associated Nephropathy.

The pathogenesis of HIV-associated nephropathy involves the complex interaction of host and environmental factors, pathogen characteristics, and patient access to antiretroviral therapy. In most cases, kidney disease does not develop in persons who have two *APOL1* risk alleles, which suggests that other factors are necessary to transform genetic risk into expression of kidney disease, such as environmental factors, coinfections, coexisting medical illnesses, or treatment effects. HIV-associated nephropathy is unique in that treatment plays a key role in mediating expression of nephropathy. Increased *APOL1* gene expression, stimulated by interferon, may be sufficient to induce glomerulopathy. Additional factors may synergize with *APOL1* variants, in which case *APOL1* variants could be seen as susceptibility factors. *APOL1* variants probably damage podocytes and other renal cells. Although injury mechanisms are not well understood, evidence points to alterations in ion flux across the plasma membrane; altered endolysosomal, mitochondrial, and autophagic function; and increased cellular inflammatory pathways, including activation of protein kinase R and effects of interferon as key pathogenic factors.

creased risk of HIV-associated immune-complex renal disease.^{48,49}

TREATMENT OF HIV-ASSOCIATED NEPHROPATHY

The use of highly active antiretroviral therapy is central to the effective treatment of HIV-associated nephropathy,⁴ especially because the kidneys are a reservoir for HIV nucleic acids, even during therapy⁵⁰; however, the importance of such agents in reducing kidney disease has not been shown in well-controlled, randomized, clinical trials. Before the introduction of anti-

retroviral therapy, HIV-associated nephropathy typically progressed rapidly to end-stage renal disease¹⁰; subsequently, HIV-associated nephropathy was considered to be an indication to initiate antiretroviral therapy.⁵¹ This approach has been superseded by a preventive approach in which antiretroviral treatment is recommended for all HIV-infected persons; such treatment may prevent HIV-associated nephropathy from progressing.⁵² Studies in sub-Saharan African populations showed increased glomerular filtration rates in affected patients after 2 to 5 years of antiretroviral therapy.^{53,54} Patients with reduced glomerular filtration rates may require dose ad-

justments of antiretroviral medications, especially nucleoside reverse transcriptase inhibitors.⁵⁵

Glucocorticoids may play a role in the treatment of HIV-associated nephropathy, but supporting evidence is limited.^{10,56} Patients with histologic evidence of dense tubulointerstitial inflammatory infiltrates may be more likely to benefit. Physicians should carefully consider the risks and benefits when prescribing immunosuppressive therapy to immunocompromised hosts.

Renin–angiotensin pathway antagonists may help decrease proteinuria and slow progressive fibrosis.^{4,10,51} Such therapy in transgenic mouse models of HIV-associated nephropathy slowed the progression of glomerular and tubular disease.^{57,58} Evidence-based blood-pressure goals for HIV-associated nephropathy — which are important to set when antagonists of the renin–angiotensin pathway are used — have not been established, but the goals may mirror those for other proteinuric kidney diseases.

HIV-ASSOCIATED IMMUNE-MEDIATED KIDNEY DISEASE

Since the beginning of the HIV pandemic, proliferative glomerulonephritides have constituted a substantial proportion of cases of HIV-associated kidney disease.^{10,27,28,49,59-63} Studies of renal-biopsy specimens from U.S. patients with HIV infection have shown that the proportion of glomerular diseases other than HIV-associated nephropathy has increased over the past two decades.^{49,60} Although it is likely that selection bias is a factor in renal-biopsy registries, HIV immune-mediated kidney disease has become the most common histopathological diagnosis in several studies of biopsy specimens from HIV-infected patients.⁴⁹ The reasons underlying the increasing relative prevalence of HIV immune-mediated kidney disease are unknown but may reflect modulation of the immune system induced by antiretroviral therapy, which can lead to immune reconstitution and immune-complex deposition, or it could be due to the decline in the incidence of HIV-associated nephropathy.⁴⁹ According to current thinking, the pathogenesis of HIV immune-mediated kidney disease involves the following distinct mechanisms: specific antibody responses to HIV epitopes and polyclonal gammopathy, both of which result in the forma-

tion of circulating immune complexes that are deposited in the glomerular capillary tuft, and in situ deposition of antibodies that bind to glomerular antigens and activate complement.^{49,61,62}

Types of HIV immune-mediated kidney disease include diverse renal histologic manifestations — HIV-associated IgA nephropathy, postinfectious glomerulonephritis, lupus-like glomerulonephritis, membranoproliferative glomerulonephritis, cryoglobulinemic glomerulonephritis, mesangial proliferative glomerulonephritis, membranous nephropathy, and other conditions that are usually characterized by glomerular hypercellularity, inflammation, and varying degrees of fibrosis and scarring (Table 1).^{49,59,61-63} Clinical features include proteinuria (often in the subnephrotic range), reduced glomerular filtration rate (usually with a progressive course), hypocomplementemia, and abnormal urinary sediment (typically with hematuria and red-cell casts).⁴⁹ Although it is difficult in clinical settings to determine whether a glomerular disease is intrinsically linked to the viral infection, clinical and experimental evidence exists to confirm the relationship of specific HIV-associated circulating immunoreactants, including idiotypic antibodies and antibodies directed against gp120, gp41, and p24, with the development of glomerulonephritis.^{49,61,62} Coinfection with other pathogens, such as hepatitis C virus, may influence the pathogenesis of HIV immune-mediated kidney disease.⁴⁹ Immune-mediated mechanisms may also underlie inflammatory cellular infiltration, causing tubulointerstitial renal diseases such as diffuse infiltrative lymphocytosis.⁶⁴

Renal biopsy is necessary to establish a diagnosis of HIV immune-mediated kidney disease.^{49,65} Determining precise etiologic relationships between the virus, immune system, and kidney injury in a particular patient requires research methods, such as immunoanalyses of tissue proteins, that are not usually possible in a clinical setting.⁴⁹ The most effective treatment of HIV immune-mediated kidney disease in the absence of evidence from randomized, controlled trials is unknown but should include antiretroviral therapy. The role of immunosuppression in the treatment of HIV immune-mediated kidney disease is controversial. In patients with crescentic glomerulonephritis, immunosuppression with glucocorticoids with or without additional

immunomodulatory therapy may be appropriate if there is no contraindication.⁴⁹

THROMBOTIC MICROANGIOPATHY IN HIV-ASSOCIATED RENAL DISEASE

Thrombotic microangiopathy is another cause of renal disease associated with HIV infection^{66,67}; this condition manifests as thrombocytopenia and microangiopathic hemolytic anemia, with or without neurologic deficits and fever. Examination of peripheral-blood smears to detect schistocytes and reduced serum haptoglobin level help in determining the diagnosis. Urinalysis often reveals hematuria and proteinuria. HIV has indirect cytopathic effects that precipitate endothelial injury, leading to thrombotic microangiopathy. HIV p24 antigen has been identified in endothelial cells of patients with thrombotic microangiopathy.⁶⁸ Coexisting medical conditions, including opportunistic infections and malignant conditions, or antiretroviral therapy may also be involved in the pathogenesis of thrombotic microangiopathy.

The development of thrombotic microangiopathy is associated with high plasma HIV viral loads and decreased CD4 counts.^{68,69} The prevalence of thrombotic microangiopathy in the United States has decreased over the past two decades, with the decrease probably attributable to effects of antiretroviral therapy.^{66,67} Therapeutic options for HIV-associated thrombotic microangiopathy include treatment of the underlying viral infection and plasma exchange. Eculizumab has been successfully used to treat thrombotic microangiopathy that is resistant to plasma exchange.⁷⁰ In the absence of data from randomized, controlled trials, immunosuppression for refractory thrombotic microangiopathy should be considered only after the potential risks and benefits in immunocompromised patients are carefully weighed.

OTHER CHRONIC KIDNEY DISEASES IN PATIENTS WITH HIV INFECTION

Prolonged therapy with antiretroviral drugs has been associated with both increased life expectancy^{2,3,5} and the development of the metabolic syndrome, diabetes mellitus, and hypertension.⁶⁹ As a result, there is an increased prevalence of

chronic medical conditions associated with renal disease in HIV-infected patients as well as in the general population.^{11-14,51} Studies of renal-biopsy specimens from HIV-infected patients suggest that the prevalences of diabetic nephropathy, hypertension-associated arterionephrosclerosis,⁶⁰ and noncollapsing focal segmental glomerulosclerosis^{60,71} are increasing because these patients are living longer and these common proteinuric chronic kidney diseases have the opportunity to develop.⁶⁰ Accelerated aging associated with chronic HIV infection may drive glomerular and vascular changes that are synergistic with diabetes, hypertension, and *APOL1* variants (Fig. 2); however, further studies are required to establish causal relationships. The effect of improved glycemic and blood-pressure control on renal outcomes in this patient population is unknown.

DRUG-INDUCED TUBULAR AND INTERSTITIAL RENAL INJURY

Renal disease may develop or worsen during antiretroviral therapy, which often presents diagnostic challenges. Antiretroviral therapy can be associated with nephrotoxic effects, including acute and chronic renal disease.^{69,72} The protease inhibitors indinavir and atazanavir are insoluble in alkaline urine and promote crystalluria and occasionally crystal nephropathy.⁷² The use of medication algorithms^{73,74} may reduce nephrotoxic effects in populations of HIV-infected patients. The diagnosis of crystal nephropathy and granulomatous interstitial nephritis is confirmed by renal biopsy (Fig. S3 in the Supplementary Appendix).^{65,72,75} Treatment of crystal nephropathy involves changing the patient's antiretroviral regimen, since alternative antiretroviral regimens are almost always available. Glucocorticoids have been used in uncontrolled studies to treat the associated interstitial nephritis, but results have been inconsistent.

Tenofovir disoproxil fumarate, which is cleared by the kidneys through glomerular filtration and active proximal renal tubular secretion, is a first-line HIV therapy. Tenofovir disoproxil fumarate enters tubular cells from the pericellular space through organic anion transporters 1 and 3 and is secreted into the tubular lumen through multidrug resistance proteins 2 and 4 and the breast cancer resistance protein 4 (Fig. 3).⁷⁶ Tenofovir

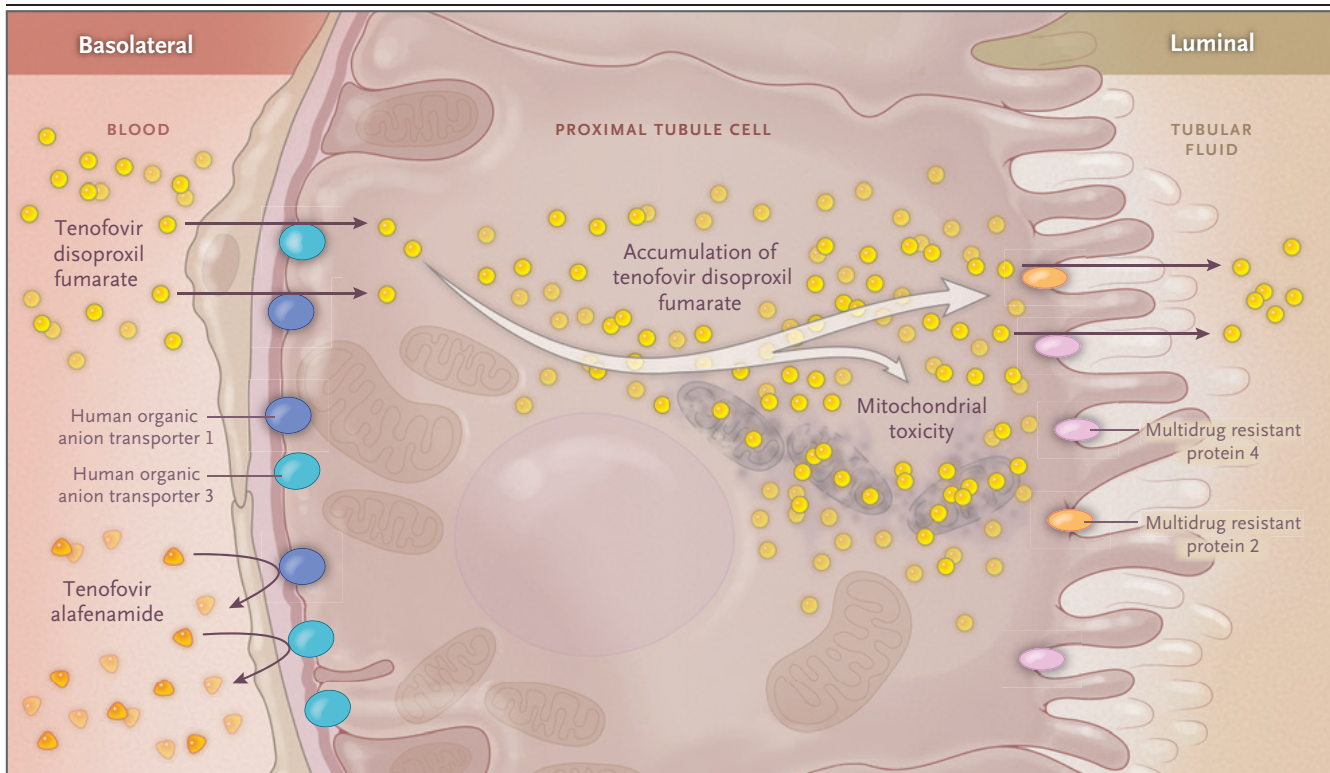


Figure 3. Handling of Tenofovir by Proximal Tubular Cells.

Tenofovir disoproxil fumarate is taken up by the organic anion transporters 1 and 3 on the basolateral membrane of the proximal tubular cell and secreted into the tubular lumen through the multidrug resistance proteins 2 and 4. The newer agent, tenofovir alafenamide, is not a substrate for organic anion transporters 1 and 3 and thus has less cellular uptake, which probably accounts for its having less nephrotoxicity than tenofovir disoproxil fumarate, as reported previously.^{76,77} Intracellular accumulation of tenofovir can cause mitochondrial toxic effects and proximal tubular injury, which can lead to Fanconi's syndrome. Clinical characteristics include proteinuria, normoglycemic glucosuria, hypophosphatemia and phosphaturia, aminoaciduria, and uricosuria and hypouricemia. Nephrogenic diabetes insipidus and acute tubular necrosis have also been described.^{72,76}

disoproxil fumarate can cause renal tubular dysfunction, which leads to Fanconi's syndrome, nephrogenic diabetes insipidus, acute tubular necrosis, and ultimately chronic kidney disease (Figs. S4 and S5 in the Supplementary Appendix).⁴ Fanconi's syndrome induced by tenofovir disoproxil fumarate results from the intracellular accumulation of the drug's metabolites that occurs because of the relatively efficient uptake of tenofovir disoproxil fumarate into the proximal tubular cell through organic anion transporters and the less efficient efflux from the proximal tubular cell through multidrug resistance proteins. Its proximal tubular cell efflux is also inhibited by commonly used antiretroviral medications, including ritonavir, thus increasing the risk of toxic effects.

The prodrug tenofovir alafenamide is associ-

ated with fewer nephrotoxic effects. Tenofovir alafenamide is not a substrate for organic anion transporters 1 and 3 and thus does not accumulate in proximal tubular cells to the extent that tenofovir disoproxil fumarate does.⁷⁷ Tenofovir alafenamide has more potent anti-HIV-1 activity and increased intracellular accumulation than tenofovir disoproxil fumarate, which yields lower levels of tenofovir in plasma.⁷⁶

The development of the immune reconstitution syndrome after initiation of antiretroviral therapy may be associated with acute kidney injury.⁷⁸ Renal pathologic features of the immune reconstitution syndrome include dense interstitial infiltrates that result from immune system reactivation. The immune reconstitution syndrome and the diffuse infiltrative lymphocytosis syndrome⁶⁴ should be considered in the dif-

ferential diagnosis of tubulointerstitial nephritis in HIV-infected patients who are receiving antiretroviral therapy (Table 1).

Measurement of urinary biomarkers has been reported to be useful in the early detection of nephrotoxic effects.⁷⁹⁻⁸¹ Patients with longer cumulative exposure to tenofovir disoproxil fumarate were shown to have progressively higher urinary α_1 -microglobulin levels, whereas patients whose treatment was discontinued had progressively lower levels — a finding that highlights the promise of urinary proteomics in the detection of early renal tubular injury.⁸¹

DIAGNOSIS AND MANAGEMENT OF CHRONIC KIDNEY DISEASE

Determining the cause of incipient and progressive renal disease in patients with HIV infection who are receiving antiretroviral therapy may be difficult. Clues can be found in the amount and character of urine protein excretion and in the urine sediment (Fig. 1). A renal biopsy may be necessary to determine diagnosis, prognosis, and management.⁶⁵

Screening for chronic kidney disease is recommended in persons with newly diagnosed HIV infection⁵¹ and includes urinalysis and measurement of serum creatinine concentration and urine protein and albumin levels in random urine samples. When the ratio of protein to creatinine is elevated in the urine, higher urine albumin-to-protein ratios help to distinguish glomerular from tubular proteinuria. Urine dipstick testing was shown to be less sensitive than quantitative urine protein measurement for identifying renal disease in HIV-infected patients.⁸² Taken together, the estimated glomerular filtration rate and the urine albumin-to-creatinine ratio provide a means to determine the stage of chronic kidney disease and may yield important prognostic and therapeutic guidance.⁸³

The effect of antiretroviral therapy on the progression of chronic kidney disease was evaluated in an observational cohort.⁸⁴ Antiretroviral therapy was associated with slower progression of chronic kidney disease, as assessed by the estimated glomerular filtration rate. Black race, lower CD4 count, higher HIV viral loads, hepatitis C virus coinfection, and particular antiretroviral medications, including tenofovir disoproxil

fumarate and ritonavir-boosted protease inhibitors, were associated with an increased risk of disease progression.

DIALYSIS AND HIV INFECTION

The life expectancy of patients with HIV-associated end-stage renal disease has increased markedly over the past 20 years.³² Although the incidence of HIV-associated end-stage renal disease has plateaued, the prevalence of HIV-infected patients undergoing dialysis in the United States continues to increase.³² Survival among patients with HIV infection who undergo dialysis is similar to that among patients without HIV infection who undergo dialysis.³² Survival among HIV-infected patients does not differ between those who undergo peritoneal dialysis and those who undergo hemodialysis.⁸⁵ Standard universal precautions apply to HIV-infected patients undergoing dialysis, and these patients do not require isolation. Peritoneal dialysate from HIV-infected persons should be considered to be a contaminated body fluid, because HIV can survive in the effluent and tubing for variable periods.⁸⁶

KIDNEY TRANSPLANTATION AND HIV INFECTION

A dramatic advance in the care of patients with HIV-associated end-stage renal disease occurred after kidney transplantation was shown to be viable.^{50,87,88} Although the rates of acute rejection are higher among HIV-infected transplant recipients than among other kidney transplant recipients, outcomes with respect to patient and allograft survival are similar.^{87,88} Candidates for renal transplantation who have HIV infection should have CD4 counts higher than 200 cells per cubic millimeter and undetectable viral loads.⁸⁷ Interactions between antiretroviral drugs and the immunosuppressive drugs needed to prevent allograft rejection necessitate close monitoring of the immunosuppressive drug level.

Findings from a recent study suggest that kidneys from donors with variant *APOL1* alleles are associated with poorer recipient outcomes than kidneys from donors without the variant alleles, but the role of genetic screening needs clarification.⁸⁹ The HIV Organ Policy Equity (HOPE) Act allows the transplantation of kidneys and

other organs from HIV-infected donors to HIV-positive recipients under the auspices of a research program,⁹⁰ thereby potentially increasing the donor pool.⁹¹

CONCLUSIONS

The spectrum of HIV-associated kidney disease has changed over the past three decades owing to far better therapy for HIV infection. During this period, evidence of nephrotoxic effects of antiretroviral therapy and the prevalence of kidney diseases resulting from aberrant metabolism and aging have increased. HIV-associated nephropathy, although much less frequent now than 20 years ago, is currently understood to arise from complex interactions among the virus (renal-cell infection and the effect of viral proteins), host genotype, host response (interferon production), and perhaps most importantly, effective treatment.

There is increasing recognition of a subgroup

of HIV-infected patients with immune-complex renal disease, which may be more prevalent as a result of generally successful HIV therapy. Kidney transplantation holds promise to increase the quantity and quality of life for patients with HIV infection in whom end-stage renal disease develops. Additional research, including well-designed randomized, controlled trials, is needed to determine effective therapeutic approaches to treating the diverse renal manifestations of HIV infection and improve the outcomes of treatment.

The opinions expressed in this article are those of the authors and do not necessarily reflect those of the National Institute of Diabetes and Digestive and Kidney Diseases (NIDDK), the National Institutes of Health, the Department of Health and Human Services, or the U.S. Government.

No potential conflict of interest relevant to this article was reported.

Disclosure forms provided by the authors are available with the full text of this article at NEJM.org.

We thank Dr. Avi Rosenberg of the NIDDK, Bethesda, MD, and Drs. Samih Nasr, Joseph Grande, Priya Alexander, and Mary Fidler of the Mayo Clinic, Rochester, MN, for the provision of clinical photomicrographs.

REFERENCES

- UNAIDS. UNAIDS fact sheet 2014 (http://files.unaids.org/en/media/unaids/contentassets/documents/factsheet/2014/20140716_FactSheet_en.pdf).
- GBD 2015 HIV Collaborators. Estimates of global, regional, and national incidence, prevalence, and mortality of HIV, 1980-2015: the Global Burden of Disease Study 2015. *Lancet HIV* 2016;3(8):e361-e387.
- Bärnighausen T. The HIV treatment cascade and antiretroviral impact in different populations. *Curr Opin HIV AIDS* 2015;10:391-4.
- Rosenberg AZ, Naicker S, Winkler CA, Kopp JB. HIV-associated nephropathies: epidemiology, pathology, mechanisms and treatment. *Nat Rev Nephrol* 2015;11:150-60.
- Notice to readers: final 2015 reports of nationally notifiable infectious diseases and conditions. *MMWR Morb Mortal Wkly Rep* 2016;65:1306-21.
- Fabian J, Naicker S. HIV and kidney disease in sub-Saharan Africa. *Nat Rev Nephrol* 2009;5:591-8.
- Fox MP, Rosen S, Geldsetzer P, Bärnighausen T, Negussie E, Beanland R. Interventions to improve the rate or timing of initiation of antiretroviral therapy for HIV in sub-Saharan Africa: meta-analysis of effectiveness. *J Int AIDS Soc* 2016;19:20888.
- Henry J. Kaiser Family Foundation. The HIV/AIDS epidemic in the United States (<https://www.kff.org/hiv/aids/fact-sheet/the-hiv-aids-epidemic-in-the-united-states-the-basics/>).
- Estrella MM, Fine DM. Screening for chronic kidney disease in HIV-infected patients. *Adv Chronic Kidney Dis* 2010;17:26-35.
- Kimmel PL, Barisoni L, Kopp JB. Pathogenesis and treatment of HIV-associated renal diseases: lessons from clinical and animal studies, molecular pathologic correlations, and genetic investigations. *Ann Intern Med* 2003;139:214-26.
- Kooman JP, van der Sande FM, Leunissen KM. Kidney disease and aging: a reciprocal relation. *Exp Gerontol* 2017;87:156-9.
- Nadkarni GN, Konstantinidis I, Wyatt CM. HIV and the aging kidney. *Curr Opin HIV AIDS* 2014;9:340-5.
- Lake JE, Currier JS. Metabolic disease in HIV infection. *Lancet Infect Dis* 2013;13:964-75.
- Calvo M, Martinez E. Update on metabolic issues in HIV patients. *Curr Opin HIV AIDS* 2014;9:332-9.
- Ryom L, Mocroft A, Kirk O, et al. Association between antiretroviral exposure and renal impairment among HIV-positive persons with normal baseline renal function: the D:A:D study. *J Infect Dis* 2013;207:1359-69.
- Franceschini N, Napravnik S, Eron JJ Jr, Szczech LA, Finn WF. Incidence and etiology of acute renal failure among ambulatory HIV-infected patients. *Kidney Int* 2005;67:1526-31.
- Cohen SD, Chawla LS, Kimmel PL. Acute kidney injury in patients with human immunodeficiency virus infection. *Curr Opin Crit Care* 2008;14:647-53.
- Chawla LS, Eggers PW, Star RA, Kimmel PL. Acute kidney injury and chronic kidney disease as interconnected syndromes. *N Engl J Med* 2014;371:58-66.
- Hadigan C, Edwards E, Rosenberg A, et al. Microalbuminuria in HIV disease. *Am J Nephrol* 2013;37:443-51.
- Overton ET, Nurutdinova D, Freeman J, Seyfried W, Mondy KE. Factors associated with renal dysfunction within an urban HIV-infected cohort in the era of highly active antiretroviral therapy. *HIV Med* 2009;10:343-50.
- Choi AI, Li Y, Parikh C, Volberding PA, Shlipak MG. Long-term clinical consequences of acute kidney injury in the HIV-infected. *Kidney Int* 2010;78:478-85.
- Wyatt CM, Schwartz GJ, Owino Ong'or W, et al. Estimating kidney function in HIV-infected adults in Kenya: comparison to a direct measure of glomerular filtration rate by iohexol clearance. *PLoS One* 2013;8(8):e69601.
- Mocroft A, Ryom L, Reiss P, et al. A comparison of estimated glomerular filtration rates using Cockcroft-Gault and the Chronic Kidney Disease Epidemiology Collaboration estimating equations in HIV infection. *HIV Med* 2014;15:144-52.
- Lee FJ, Carr A. Tolerability of HIV integrase inhibitors. *Curr Opin HIV AIDS* 2012;7:422-8.
- German P, Liu HC, Szwarcberg J, et al. Effect of cobicistat on glomerular filtration rate in subjects with normal and impaired renal function. *J Acquir Immune Defic Syndr* 2012;61:32-40.

26. Sreepada Rao TK, Filippone EJ, Nicas-tri AD, et al. Associated focal and segmen-tal glomerulosclerosis in the acquired im-munodeficiency syndrome. *N Engl J Med* 1984;310:669-73.
27. Pardo V, Aldana M, Colton RM, et al. Glomerular lesions in the acquired im-munodeficiency syndrome. *Ann Intern Med* 1984;101:429-34.
28. Gardenswartz MH, Lerner CW, Selig-son GR, et al. Renal disease in patients with AIDS: a clinicopathologic study. *Clin Nephrol* 1984;21:197-204.
29. Heymann J, Winkler CA, Hoek M, Susztak K, Kopp JB. Therapeutics for APOL1 nephropathies: putting out the fire in the podocyte. *Nephrol Dial Transplant* 2017;32:Suppl 1:i65-i70.
30. Dijkman HB, Weening JJ, Smeets B, et al. Proliferating cells in HIV and pamir-sonate-associated collapsing focal segmen-tal glomerulosclerosis are parietal epi-thelial cells. *Kidney Int* 2006;70:338-44.
31. Mallipattu SK, Wyatt CM, He JC. The new epidemiology of HIV-related kidney disease. *J AIDS Clin Res* 2012;Suppl 4:001.
32. Razzak Chaudhary S, Workeneh BT, Montez-Rath ME, Zolopa AR, Klotman PE, Winkelmayer WC. Trends in the out-comes of end-stage renal disease second-ary to human immunodeficiency virus-associated nephropathy. *Nephrol Dial Transplant* 2015;30:1734-40.
33. Genovese G, Friedman DJ, Ross MD, et al. Association of trypanolytic ApoL1 variants with kidney disease in African Americans. *Science* 2010;329:841-5.
34. Tzur S, Rosset S, Shemer R, et al. Mis-sense mutations in the APOL1 gene are highly associated with end stage kidney disease risk previously attributed to the MYH9 gene. *Hum Genet* 2010;128:345-50.
35. Raper J, Fung R, Ghiso J, Nussenzweig V, Tomlinson S. Characterization of a novel trypanosome lytic factor from human se-rum. *Infect Immun* 1999;67:1910-6.
36. Cooper A, Ilboudo H, Alibu VP, et al. APOL1 renal risk variants have contrast-ing resistance and susceptibility associa-tions with African trypanosomiasis. *Elife* 2017;6:e25461.
37. Kopp JB, Nelson GW, Sampath K, et al. APOL1 genetic variants in focal segmen-tal glomerulosclerosis and HIV-associated nephropathy. *J Am Soc Nephrol* 2011;22:2129-37.
38. Kasembeli AN, Duarte R, Ramsay M, et al. APOL1 risk variants are strongly as-sociated with HIV-associated nephropa-thy in black South Africans. *J Am Soc Nephrol* 2015;26:2882-90.
39. Kruzel-Davila E, Shemer R, Ofir A, et al. APOL1-mediated cell injury involves disruption of conserved trafficking pro-cesses. *J Am Soc Nephrol* 2017;28:1117-30.
40. Fu Y, Zhu JY, Richman A, et al. APOL1-G1 in nephrocytes induces hypertrophy and accelerates cell death. *J Am Soc Nephrol* 2017;28:1106-16.
41. Beckerman P, Bi-Karchin J, Park ASD, et al. Transgenic expression of human APOL1 risk variants in podocytes induces kidney disease in mice. *Nat Med* 2017;23:429-38.
42. Sauter D, Kirchhoff F. HIV replication: a game of hide and sense. *Curr Opin HIV AIDS* 2016;11:173-81.
43. Nichols B, Jog P, Lee JH, et al. Innate immunity pathways regulate the nephrop-athy gene Apolipoprotein L1. *Kidney Int* 2015;87:332-42.
44. Hayek SS, Koh KH, Grams ME, et al. A tripartite complex of suPAR, APOL1 risk variants and $\alpha\beta3$ integrin on podo-cytes mediates chronic kidney disease. *Nat Med* 2017;23:945-53.
45. Barisoni L, Schnaper HW, Kopp JB. A proposed taxonomy for the podocytop-athies: a reassessment of the primary ne-phrotic diseases. *Clin J Am Soc Nephrol* 2007;2:529-42.
46. Olabisi OA, Zhang JY, VerPlank L, et al. APOL1 kidney disease risk variants cause cytotoxicity by depleting cellular potassium and inducing stress-activated protein kinases. *Proc Natl Acad Sci U S A* 2016;113:830-7.
47. Ma L, Chou JW, Snipes JA, et al. APOL1 renal-risk variants induce mito-chondrial dysfunction. *J Am Soc Nephrol* 2017;28:1093-105.
48. Fine DM, Wasser WG, Estrella MM, et al. APOL1 risk variants predict histopa-thology and progression to ESRD in HIV-related kidney disease. *J Am Soc Nephrol* 2012;23:343-50.
49. Nobakht E, Cohen SD, Rosenberg AZ, Kimmel PL. HIV-associated immune com-plex kidney disease. *Nat Rev Nephrol* 2016;12:291-300.
50. Avettand-Fenoël V, Rouzioux C, Legen-dre C, Canaud G. HIV infection in the na-tive and allograft kidney: implications for management, diagnosis and transplanta-tion. *Transplantation* 2017;101:2003-8.
51. Lucas GM, Ross MJ, Stock PG, et al. Clinical practice guideline for the man-agement of chronic kidney disease in pa-tients infected with HIV: 2014 update by the HIV Medicine Association of the In-fectious Diseases Society of America. *Clin Infect Dis* 2014;59(9):e96-e138.
52. Vital signs: HIV prevention through care and treatment — United States. *MMWR Morb Mortal Wkly Rep* 2011;60:1618-23.
53. Stöhr W, Reid A, Walker AS, et al. Glomerular dysfunction and associated risk factors over 4-5 years following anti-retroviral therapy initiation in Africa. *Anti-vir Ther* 2011;16:1011-20.
54. Mpondo BC, Kalluvya SE, Peck RN, et al. Impact of antiretroviral therapy on renal function among HIV-infected Tan-zanian adults: a retrospective cohort study. *PLoS One* 2014;9(2):e89573.
55. Berns JS, Kasbekar N. Highly active antiretroviral therapy and the kidney: an update on antiretroviral medications for nephrologists. *Clin J Am Soc Nephrol* 2006;1:117-29.
56. Eustace JA, Nuermberger E, Choi M, Scheel PJ Jr, Moore R, Briggs WA. Cohort study of the treatment of severe HIV-asso-ciated nephropathy with corticosteroids. *Kidney Int* 2000;58:1253-60.
57. Bird JE, Durham SK, Giancarli MR, et al. Captopril prevents nephropathy in HIV-transgenic mice. *J Am Soc Nephrol* 1998;9:1441-7.
58. Kumar D, Plagov A, Yadav I, et al. In-hibition of renin activity slows down the progression of HIV-associated nephropa-thy. *Am J Physiol Renal Physiol* 2012;303:F711-F720.
59. Campos P, Ortiz A, Soto K. HIV and kidney diseases: 35 years of history and consequences. *Clin Kidney J* 2016;9:772-81.
60. Wyatt CM, Morgello S, Katz-Malamed R, et al. The spectrum of kidney disease in patients with AIDS in the era of antire-troviral therapy. *Kidney Int* 2009;75:428-34.
61. Kimmel PL, Phillips TM, Ferreira-Centeno A, Farkas-Szallasi T, Abraham AA, Garrett CT. Idiopathic IgA nephropa-thy in patients with human immunodef-iciency virus infection. *N Engl J Med* 1992;327:702-6.
62. Kimmel PL, Phillips TM, Ferreira-Centeno A, Farkas-Szallasi T, Abraham AA, Garrett CT. HIV-associated immune-mediated renal disease. *Kidney Int* 1993;44:1327-40.
63. Booth JW, Hamzah L, Jose S, et al. Clinical characteristics and outcomes of HIV-associated immune complex kidney disease. *Nephrol Dial Transplant* 2016;31:2099-107.
64. Ghrenassia E, Martis N, Boyer J, Burel-Vandenbos F, Mekinian A, Coppo P. The diffuse infiltrative lymphocytosis syn-drome (DILS): a comprehensive review. *J Autoimmun* 2015;59:19-25.
65. Cohen SD, Kimmel PL. Renal biopsy is necessary for the diagnosis of HIV-asso-ciated renal diseases. *Nat Clin Pract Nephrol* 2009;5:22-3.
66. Becker S, Fusco G, Fusco J, et al. HIV-associated thrombotic microangiopathy in the era of highly active antiretroviral ther-apy: an observational study. *Clin Infect Dis* 2004;39:Suppl 5:S267-75.
67. Gervasoni C, Ridolfo AL, Vaccarezza M, et al. Thrombotic microangiopathy in patients with acquired immunodeficiency syndrome before and during the era of in-troduction of highly active antiretroviral therapy. *Clin Infect Dis* 2002;35:1534-40.
68. del Arco A, Martinez MA, Peña JM, et al. Thrombotic thrombocytopenic purpura associated with human immunodeficiency virus infection: demonstration of p24 antigen in endothelial cells. *Clin Infect Dis* 1993;17:360-3.
69. Izzedine H, Deray G. The nephrologist in the HAART era. *AIDS* 2007;21:409-21.

70. Jin A, Boroujerdi-Rad L, Shah G, Chen JL. Thrombotic microangiopathy and human immunodeficiency virus in the era of eculizumab. *Clin Kidney J* 2016;9:576-9.
71. Meehan SM, Kim L, Chang A. A spectrum of morphologic lesions of focal segmental glomerulosclerosis by Columbia criteria in human immunodeficiency virus infection. *Virchows Arch* 2012;460:429-35.
72. Izzedine H, Harris M, Perazella MA. The nephrotoxic effects of HAART. *Nat Rev Nephrol* 2009;5:563-73.
73. Mocroft A, Lundgren JD, Ross M, et al. Development and validation of a risk score for chronic kidney disease in HIV infection using prospective cohort data from the D:A:D study. *PLoS Med* 2015;12(3):e1001809.
74. Scherzer R, Gandhi M, Estrella MM, et al. A chronic kidney disease risk score to determine tenofovir safety in a prospective cohort of HIV-positive male veterans. *AIDS* 2014;28:1289-95.
75. Mallipattu SK, Salem F, Wyatt CM. The changing epidemiology of HIV-related chronic kidney disease in the era of antiretroviral therapy. *Kidney Int* 2014;86:259-65.
76. Wyatt CM. Will a new tenofovir prodrug for the treatment of HIV reduce the risk of nephrotoxicity? *Kidney Int* 2016;89:5-6.
77. Gibson AK, Shah BM, Nambiar PH, Schafer JJ. Tenofovir alafenamide. *Ann Pharmacother* 2016;50:942-52.
78. Daugas E, Plaisier E, Boffa JJ, et al. Acute renal failure associated with immune restoration inflammatory syndrome. *Nat Clin Pract Nephrol* 2006;2:594-8.
79. Peralta C, Scherzer R, Grunfeld C, et al. Urinary biomarkers of kidney injury are associated with all-cause mortality in the Women's Interagency HIV Study (WIHS). *HIV Med* 2014;15:291-300.
80. Shlipak MG, Scherzer R, Abraham A, et al. Urinary markers of kidney injury and kidney function decline in HIV-infected women. *J Acquir Immune Defic Syndr* 2012;61:565-73.
81. Jotwani V, Scherzer R, Estrella MM, et al. HIV infection, tenofovir disoproxil fumarate, and urine alpha1-microglobulin: a cross-sectional analysis in the Multi-center AIDS Cohort Study. *Am J Kidney Dis* 2016;68:571-81.
82. Siedner MJ, Atta MG, Lucas GM, Perazella MA, Fine DM. Poor validity of urine dipstick as a screening tool for proteinuria in HIV-positive patients. *J Acquir Immune Defic Syndr* 2008;47:261-3.
83. Kidney Disease: Improving Global Outcomes (KDIGO) CKD Work Group. KDIGO clinical practice guideline for the evaluation and management of chronic kidney disease. *Kidney Int Suppl* 2013;3:1-150.
84. Kalayjian RC, Lau B, Mechekeano RN, et al. Risk factors for chronic kidney disease in a large cohort of HIV-1 infected individuals initiating antiretroviral therapy in routine care. *AIDS* 2012;26:1907-15.
85. Soleymanian T, Raman S, Shannaq FN, et al. Survival and morbidity of HIV patients on hemodialysis and peritoneal dialysis: one center's experience and review of the literature. *Int Urol Nephrol* 2006;38:331-8.
86. Farzadegan H, Ford D, Malan M, Masters B, Scheel PJ Jr. HIV-1 survival kinetics in peritoneal dialysis effluent. *Kidney Int* 1996;50:1659-62.
87. Stock PG, Barin B, Murphy B, et al. Outcomes of kidney transplantation in HIV-infected recipients. *N Engl J Med* 2010;363:2004-14.
88. Sawinski D, Bloom RD. Current status of kidney transplantation in HIV-infected patients. *Curr Opin Nephrol Hypertens* 2014;23:619-24.
89. Freedman BI, Julian BA. Should kidney donors be genotyped for APOL1 risk alleles? *Kidney Int* 2015;87:671-3.
90. Boyarsky BJ, Durand CM, Palella FJ Jr, Segev DL. Challenges and clinical decision-making in HIV-to-HIV transplantation: insights from the HIV literature. *Am J Transplant* 2015;15:2023-30.
91. Muller E, Barday Z, Mendelson M, Kahn D. HIV-positive-to-HIV-positive kidney transplantation — results at 3 to 5 years. *N Engl J Med* 2015;372:613-20.

Copyright © 2017 Massachusetts Medical Society.

IMAGES IN CLINICAL MEDICINE

The *Journal* welcomes consideration of new submissions for Images in Clinical Medicine. Instructions for authors and procedures for submissions can be found on the *Journal's* website at NEJM.org. At the discretion of the editor, images that are accepted for publication may appear in the print version of the *Journal*, the electronic version, or both.